

Early laparoscopy for ileocolic intussusception with multiple recurrences in children

Yu-Tang Chang · Jui-Ying Lee · Jaw-Yuan Wang ·
Chi-Shu Chiou · Jan-You Lin

Received: 14 September 2007 / Accepted: 3 May 2008
© Springer Science+Business Media, LLC 2008

Abstract

Background The risks of subsequent episodes and a lead point are common problems in ileocolic intussusception with more than two recurrences. To decrease subsequent recurrence and to detect a lead point, an early laparoscopy was performed for children with ileocolic intussusception.

Methods This study enrolled six children with multiple recurrences of ileocolic intussusception from January 2004 to August 2007. Using a 5-mm laparoscope and two additional transabdominal wall stab incisions, an appendectomy and an ileocolonic pixie with nonabsorbable sutures were performed simultaneously for all the children after the last successful hydrostatic reduction.

Results The mean operating time was 68.8 ± 12.6 min (range, 55–86 min). There was no operative morbidity, and no lead point was found in any child. The mean follow-up period was 10.8 ± 6.7 months (range, 2–20 months). No recurrence was observed during this period.

Conclusion The authors suggest that early intervention should be undertaken for ileocolic intussusception with multiple recurrences in children after the last nonsurgical reduction has been attempted successfully. Under this strategy, laparoscopy is an acceptable approach. It allows differentiation of a specific etiologic lesion, the possibility of incomplete reduction, and additional proximal invaginations. Later complications, such as repeat recurrence and associated surgical morbidity, also can be avoided.

Keywords Children · Intussusception · Laparoscopy · Recurrence

Intussusception is the most common cause of bowel obstruction in infants and children. Recurrence after reduction of intussusception is a well-recognized condition, with an incidence varying from 2% to 20% of cases [1]. According to most reports in the literature, children with recurrent intussusception are managed initially with non-surgical reduction by insufflation of air or hydrostatic enema [2–5], with surgical treatment reserved for patients with irreducible recurrence or evidence of a lead point [1].

Under this strategy, however, a large discrepancy in prognosis among children with this condition was noted. For 10.1% to 57.1% of the children with irreducible recurrent intussusception, emergent open reduction surgery was needed [2–4]. In 12.5% to 25% of these emergency cases, immediate resection due to gangrenous bowel was required although there was no specific lead point [2, 3].

Under emergent or complicated circumstances, standard laparotomy still is a safe procedure. With the advent of minimally invasive surgery, some authors have considered laparoscopy to be a valid treatment for irreducible intussusception [6–9]. However, its effectiveness for such cases remains doubtful because the intraoperative conversion rate could exceed 79.6% [9].

Since January 2004, an earlier and more aggressive laparoscopic approach for intussusception with more than two recurrences (i.e., early laparoscopy in a stable situation after successful hydrostatic reduction) has been used in our institution. Through this approach, the authors attempt to decrease subsequent recurrences for selected patients and lower the risk of further emergent open surgery.

Yu-Tang Chang · J.-Y. Lee · J.-Y. Wang · C.-S. Chiou ·
J.-Y. Lin (✉)
Department of Surgery, Faculty of Medical School,
Division of Pediatric Surgery, Kaohsiung Medical University
Hospital, 100 Tzyou 1st Road, Kaohsiung 80708, Taiwan
e-mail: 890300@ms.kmuh.org.tw

Materials and methods

Between January 2004 and August 2007, a total of 81 consecutive children with intussusception treated and followed by the same surgical team were reviewed. During this period, intussusception was diagnosed at our institution primarily by ultrasonography, and an initial reduction attempt was made hydrostatically under sonographic guidance. One patient for whom hydrostatic reduction was contraindicated initially underwent open reduction. For 75 (93.75%) of the remaining 80 children, saline hydrostatic reduction was successful. Reduction failed for the remaining 5 patients, necessitating emergent open reduction.

Among the patients who had successful hydrostatic reduction, emergent diagnostic laparoscopy was performed in one case because the success of hydrostatic reduction could not be determined by ultrasonography. In addition, 13 patients (16.3%) experienced 24 recurrences. Of these 13 patients, 7 had two intussusceptions (i.e., 1 recurrence) and 6 had three to seven intussusceptions (i.e., 2–6 recurrences). The six patients with multiple recurrences included five boys and one girl who at presentation for their first intussusception ranged in age from 5 months to 32 months (mean, 16.5 ± 9.8 months). None of these children had a systemic underlying disease, and all had ileocolic intussusception.

Successful reduction by saline hydrostatic enema was achieved in all the initial episodes and recurrences. Laparoscopy was performed after the last successful hydrostatic reduction.

Operative technique

After induction of general anesthesia and gastric decompression, the patient was placed in a supine position. The first 5-mm trocar was introduced through the umbilicus using an open method. The abdomen was insufflated to 12 mmHg, and a 5-mm 30° laparoscope (Karl Storz GmbH & Co, Tuttlingen, Germany) was introduced into the peritoneal cavity. Under direct vision, two selective operative instruments were placed directly through transabdominal wall stab incisions at the right upper and left lower quadrants as previously described [10].

First, the patient was placed in reverse Trendelenburg position with the left side of the table tilted down. The cecum was identified initially, and the small bowel was carefully examined for evidence of associated pathology. Second, elective appendectomy was performed. Third, the cecum, the stump of appendix, and the terminal ileum were sutured to the lateral peritoneum (ileocolonic pixie) with silk or 3-0 polydioxanone using the technique of intracorporeal knot tying (Fig. 1) [9, 11]. Finally, the umbilical incision was sutured. No stitches were required for two transabdominal stab incisions.

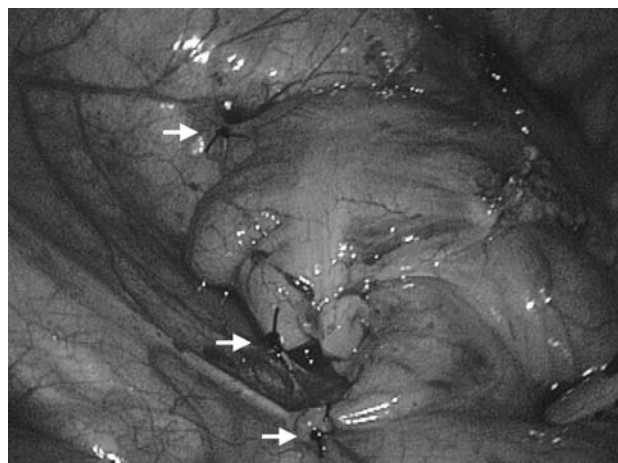


Fig. 1 Note the cecum, the base of the appendix, and the terminal ileum fixed to the right lateral abdominal wall with three nonabsorbable stitches (arrows)

Results

The patients' ages at surgery ranged from 15 to 36 months (mean, 26.8 ± 8.6 months). The surgery was performed 3 days to 28 months after the initial episode.

All the patients did well during the procedure, and no operative morbidity was experienced. The mean operating time was 68.8 ± 12.6 min (range, 55–86 min). For one patient who experienced six recurrences within 24 h, the intussusception kept recurring during laparoscopy, and reduction was smoothly accomplished with atraumatic graspers. No lead point was found in any of the children, and ileocolonic pixie was performed. Only surrounding hypertrophied lymphoid tissue was found and excised for pathology (Fig. 2).

The pathologic examinations showed reactive hyperplasia. A patent processus vaginalis found in two patients

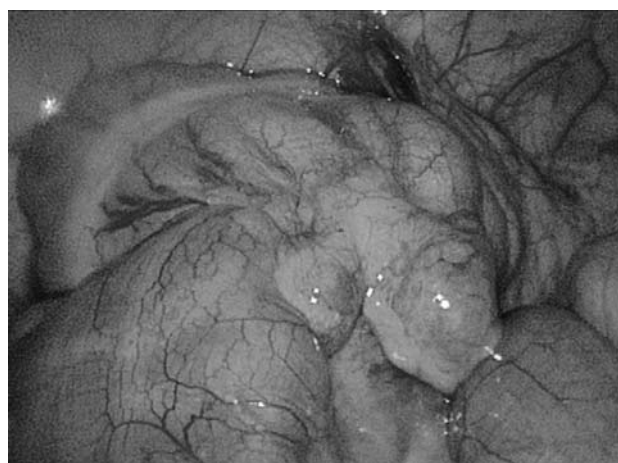


Fig. 2 Note the hyperplastic lymphoid tissue and the terminal ileum ready to invaginate again

was closed by percutaneously extracorporeal knot tying [12]. All six children treated for multiple recurrences were discharged after 2 to 3 days. The mean follow-up period was 10.8 ± 6.7 months (range, 2–20 months). At this writing, there have been no recurrences.

Discussion

Intussusception with multiple recurrences is experienced by 17% and 44.4% of children with recurrent intussusception [1–5], and the risk of subsequent episodes increases after the first recurrence [3]. The incidence of recurrence in the current series was comparable with that in reported studies. Although one-third of recurrences happen within 1 day and three-fourths occur within 6 months [1, 3, 4], a recurrent episode has been reported 9 years after the initial intussusception [4].

The clinical symptoms of recurrent intussusception usually are fewer and milder than in the initial episode [1, 3–5]. However, the etiology of most recurrent intussusceptions is unknown, and there is no predisposing factor to predict whether the intussusception will recur or not [3, 11]. Unnecessary calls may be made by anxious parents when some intercurrent illness mimics the condition.

The management of intussusception with multiple recurrences still is undetermined, and the appropriate delay until surgical intervention is of great concern for clinicians [4]. Recurrent intussusception usually has no defined lead point [1], but multiple recurrences are associated with a higher lead point incidence than only one recurrence [2, 4].

Early on, most investigators advocated surgical intervention after the second or third recurrence [11, 13]. Soper and Brown [11] suggested that surgical intervention is necessary to differentiate the possibilities of incomplete reduction, additional proximal invaginations, and the presence of specific etiologic lesions. However, the prophylactic procedure has not become standard operative procedure since then because traditional laparotomy causes a large, noticeable scar and may be of little value [14].

Recently, some authors have recommended nonsurgical reduction if intussusception occurs again [2, 4, 5]. However, successful nonsurgical reduction also cannot completely exclude a lead point [4], and the pattern of recurrence cannot predict the presence of a lead point [2]. Fecteau et al. [4] suggested that enema reduction is safe and has a good success rate for cases of recurrent intussusception, but five (83.3%) of their six children with multiple recurrences finally required emergent open reduction.

With the advances in endoscopic techniques and equipment, sporadic reports describe laparoscopy used for intussusception with multiple recurrences [2, 15]. Because of the excellent cosmetic results and minimal invasiveness

of laparoscopy, it may be considered as an aggressive therapy for cases with multiple recurrences. The less invasive technique satisfactory answered the three possibilities assumed by Soper and Brown [11]. In addition, we also evaluated the presence of a patent processus vaginalis and closed it by percutaneous extracorporeal knot tying if present so the defect could not be visualized. In this case, the procedure could not be performed under traditional laparotomy.

Our institution was able to achieve a high success rate for hydrostatic reduction. It is probable that these nonsurgical reductions were performed aggressively by the pediatric surgeons instead of the radiologist, who may not have been responsible for bowel perforation. In a medical center such as ours with good facilities for the nonsurgical reduction of intussusception, laparoscopy is performed primarily for children with multiple recurrences and those for whom sonographic examination did not determine whether reduction was complete.

The management of occult inguinal hernia during laparoscopy for other reasons has not been debated. Some specialists regard hernioplasty as not needed for an asymptomatic inguinal defect [16], whereas others suggest that simultaneous repair is justifiable because a significant proportion of incidental defects will progress to symptomatic hernias if left untreated [17]. In children, a patent processus vaginalis shorter than 20 mm may not develop into a clinical hernia [12]. Based on this, a large patent processus vaginalis may be closed during laparoscopy.

A number of limitations in this study have been identified. The major drawback is the limited number of cases even though there was no recurrence after laparoscopy. Certainly, more long-term follow-up evaluation concerning the recurrence rate is necessary. However, with the current trend toward minimally invasive surgery, we were able to evaluate the application and advantages of this simple procedure for selected patients. Some doctors would be concerned about possible overtreatment of intussusception with multiple recurrences, which may be merely incomplete reduction or could possibly be resolved by repeat nonsurgical reduction.

At our institution, with its excellent experience using hydrostatic reduction, at the first recurrence, we would attempt reduction very cautiously by ensuring free passage of saline into the distal small intestine and searching for a probable lead point. However, we have never observed a recurrent intussusception caused by a lead point, and an unexpected second recurrence or more recurrences eventually occurred for these children. Even when no obvious lead point is present, we have been able to perform the ileocolonic pixie through the less invasive technique.

Concomitant appendectomy also has been performed to increase regional adhesions and prevent the mobility

necessary for intussusception to recur [11]. Moreover, as the current series showed, early laparoscopy was performed for children in a stable condition. Subsequent recurrence and associated surgical morbidity caused by failed nonsurgical reduction could be nonexistent.

We affirm that early laparoscopy is a feasible strategy for intussusception with multiple recurrences due to no predisposing etiology where there is a risk of subsequent episodes and lead point. Early laparoscopy may identify a specific etiologic lesion, the possibility of incomplete reduction, and additional proximal invaginations. Consequently, later complications such as repeat recurrence, which may need open reduction and associated surgical morbidity, also can be avoided.

References

1. Fallat ME (2005) Intussusception. In: Ashcraft KW, Holcomb GW III, Murphy JP (eds) *Pediatric surgery*. Elsevier Saunders, Philadelphia, PA, pp 533–542
2. Daneman A, Alton DJ, Lobo E, Gravett J, Kim P, Ein SH (1998) Patterns of recurrence of intussusception in children: a 17-year review. *Pediatr Radiol* 28:913–919
3. Ein SH (1975) Recurrent intussusception in children. *J Pediatr Surg* 10:751–755
4. Fecteau A, Flageole H, Nguyen LT, Laberge JM, Shaw KS, Guttman FM (1996) Recurrent intussusception: safe use of hydrostatic enema. *J Pediatr Surg* 31:859–861
5. Yang CM, Hsu HY, Tsao PN, Chang MH, Lin FY (2001) Recurrence of intussusception in childhood. *Acta Paediatr Taiwan* 42:158–161
6. Hay SA, Kabesh AA, Soliman HA, Abdelrahman AH (1999) Idiopathic intussusception: the role of laparoscopy. *J Pediatr Surg* 34:577–578
7. Kia KF, Mony VK, Drongowski RA, Golladay ES, Geiger JD, Hirschl RB, Coran AG, Teitelbaum DH (2005) Laparoscopic vs open surgical approach for intussusception requiring operative intervention. *J Pediatr Surg* 40:281–284
8. Schier F (1997) Experience with laparoscopy in the treatment of intussusception. *J Pediatr Surg* 32:1713–1714
9. van der Laan M, Bax NM, van der Zee DC, Ure BM (2001) The role of laparoscopy in the management of childhood intussusception. *Surg Endosc* 15:373–376
10. Ostlie DJ, Holcomb GW III (2003) The use of stab incisions for instrument access in laparoscopic operations. *J Pediatr Surg* 38:1837–1840
11. Soper RT, Brown MJ (1964) Recurrent acute intussusception in children. *Arch Surg* 89:188–198
12. Oue T, Kubota A, Okuyama H, Kawahara H (2005) Laparoscopic percutaneous extraperitoneal closure (LPEC) method for the exploration and treatment of inguinal hernia in girls. *Pediatr Surg Int* 21:964–968
13. Burrington JD (1980) Surgical technique for the prevention of recurrent intussusception in childhood. *Surg Gynecol Obstet* 150:572–573
14. Koh CC, Sheu JC, Wang NL, Lee HC, Chang PY, Yeh ML (2006) Recurrent ileocolic intussusception after different surgical procedures in children. *Pediatr Surg Int* 22:725–728
15. Boehm R, Till H (2003) Recurrent intussusceptions in an infant that were terminated by laparoscopic ileocolonic pexie. *Surg Endosc* 17:831–832
16. Paaanan H, Ojala S, Virkkunen A. (2006) Incidence of occult inguinal and Spigelian hernias during laparoscopy of other reasons. *Surgery* 140:9–12
17. Thumbe VK, Evans DS (2001) To repair or not to repair incidental defects found on laparoscopic repair of groin hernia: early results of a randomized control trial. *Surg Endosc* 15:47–49